

Giant Cell Granuloma of the Maxillary Bone

Sedat Aydın¹ , Mehmet Gökhan Demir² , Burak Dikmen¹ , Nazmiye Yoğurtcu Ünlü¹ , Sibel Kayahan³ 

¹Department Otorhinolaryngology, Health Sciences University, Kartal Dr. Lutfi Kırdar Training and Research Hospital, İstanbul, Turkey

²Department Otorhinolaryngology, Prof. Dr. Celal Ertuğ Etimesgut State Hospital, Ankara, Turkey

³Department of Pathology, Health Sciences University, Kartal Dr. Lutfi Kırdar Training and Research Hospital, İstanbul, Turkey

Abstract

Reactive hyperplastic lesions in oral cavity are benign tumors that cause local symptoms and complications. Underlying pathologic mechanism is still uncertain but local irritant factors might be the reason. Giant cell granuloma is one of the most common forms of the reactive hyperplastic lesions. They can be located on jaw and maxillary bone at the level of premolar and incisive teeth. Most of the lesions are <1.5 cm in diameter. Tumors which are detected on maxillary bone and >1.5 cm in diameter are rare. Main treatment modality is to completely excise the lesion to decrease the chance of recurrence. In this report we present a maxillary bone tumor (3 × 3 cm in size) that is treated successfully by surgery after recurrence.

Keywords: Giant cell tumor, maxillary bone, molar tooth

INTRODUCTION

Reactive hyperplastic lesions in the oral cavity are commonly seen, but the real causes are still unknown. Many disturbing factors, such as tobacco use inflammation, and foreign body reaction can cause these lesions (1). These hyperplastic lesions have been grouped as pyogenic granuloma, peripheral giant cell granuloma (PGCG), peripheral ossifying fibroma, and irritation fibroma (IF) (2). PGCG in the oral cavity is often <1.5 cm and asymptomatic. Lesions >1.5 cm are rare and they may cause bleeding and tooth loss. Maxillary bones and mandible are the regions that are mostly involved. The lesion is mostly located at the level of premolar and molar regions. It is more frequent in females and the incidence increases in the 5th and 6th decades of life (3). In this article, we would like to present a case of recurrent and symptomatic PGCG in the maxillary region which we treated with surgical excision.

CASE PRESENTATION

A 25-year-old female patient visited the out patient clinic with complaints of swelling in upper right molar teeth for a year. A bleeding, painless, and slowly growing lesion during tooth brushing was described in the history. Smoking was also mentioned in the anamnesis. During the examination, a 2 × 3 cm mass was detected in the medial portion of the right upper molar region (Figure 1). The lesion was excised by the dentist when first detected, but it recurred within 3 weeks. Pathologic examination reported it as a peripheral giant cell granuloma (PGCG). After this recurrence, the patient was referred to the otorhinolaryngology department. In the computed tomography examination, an 18 × 17 mm right-sided maxillary lesion which had minimal contrast involvement and caused erosion in cheek tissues was observed. In T2-weighted diffusion magnetic resonance imaging -axial sections, a 17 × 18 mm homogeneous mass that was contrast enhancing and apparently circumscribed was found in the right posteromedial dental arcus of the maxillary bone (Figure 2). After receiving the written informed consent from the patient, the lesion was totally excised with the accompanying teeth (Figure 3).

Postoperative recovery was achieved without any problems and no complaints were recorded from the patient. Pathological diagnosis reported the lesion as a PGCG with osteoclast-type giant cell groups in fibrous stroma (Figure 4).

Cite this article as: Aydın S, Demir MG, Dikmen B, Yoğurtcu Ünlü N, Kayahan S. Giant Cell Granuloma of the Maxillary Bone. Eur J Rhinol Allergy 2018; 1: 21-3

This paper was presented as a poster in 13th Turkish Rhinology 5th National Otolaryngology Neurotology 1st National Head Neck Surgery Congress, 4-7 May 2017, Antalya, Turkey

Address for Correspondence: Sedat Aydın

E-mail: sedataydin63@yahoo.com

Received: 27.09.2017

Accepted: 15.12.2017

DOI: 10.5152/ejra.2018.58109

©Copyright 2018 by Turkish Rhinologic Society - Available online at www.eurjrhinol.org

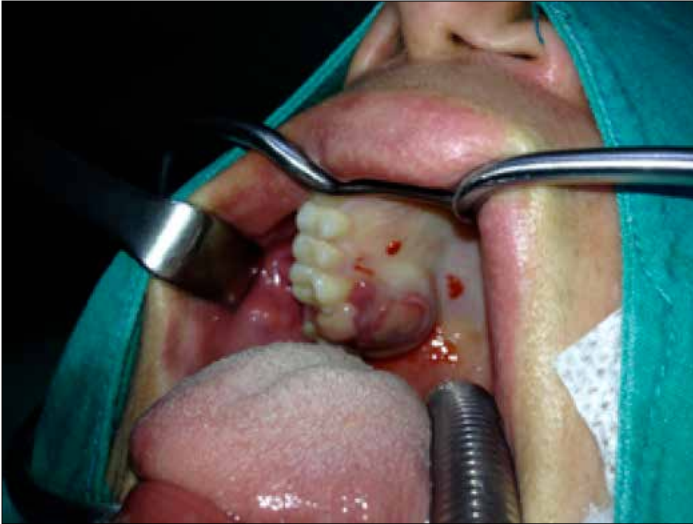

Figure 1. Preoperative view of the lesion in the maxillary molar region

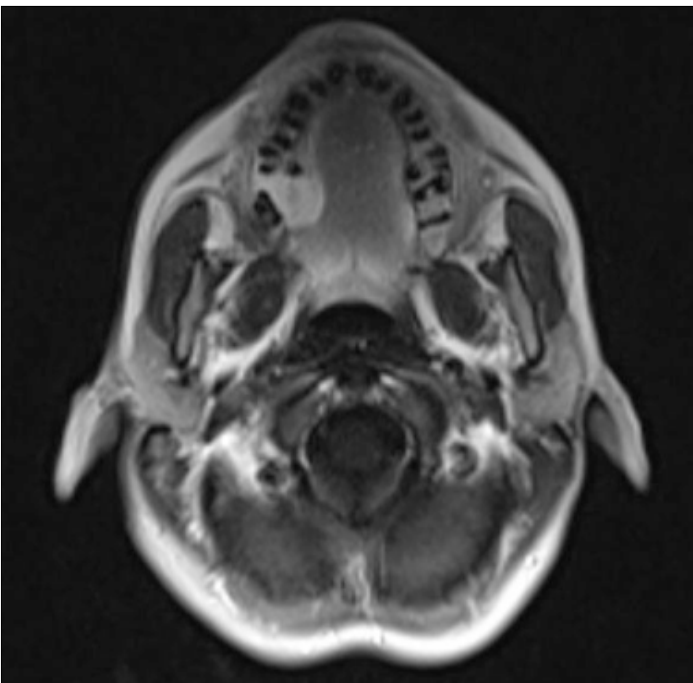


Figure 2. T2-weighted MR-axial sections; a 17×18 mm homogeneous mass that is contrast enhancing and apparently circumscribed in the right posteromedial dental arcus of the maxillary bone

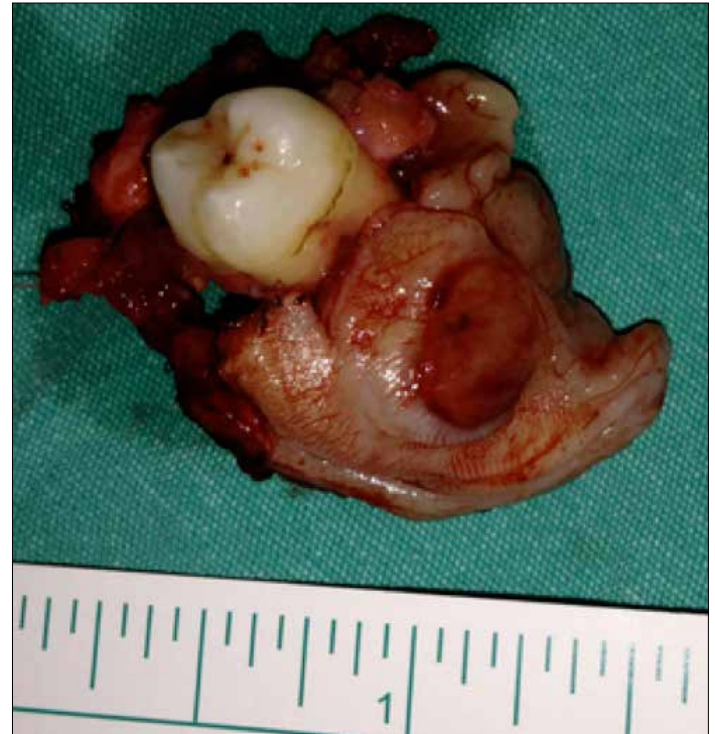

Figure 3. Macroscopic view of the excised tumor

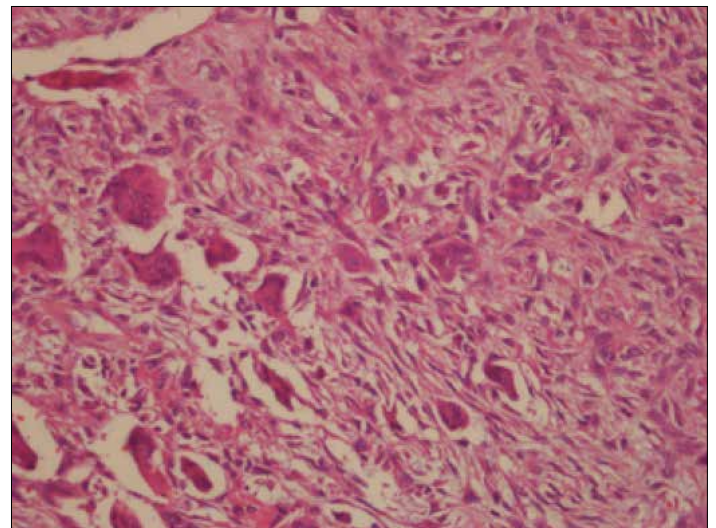


Figure 4. Osteoclast giant cell groups in the fibrous stroma (HE×40)

DISCUSSION

Peripheral giant cell granuloma is one of the hyperplastic oral cavity lesions and constitutes <10% of the lesions in the gingival region. Many of the cases are small and asymptomatic and can be observed at any age. Lesions >1.5 cm are rare and can be symptomatic as observed in our case. Surgical excision should be carefully and thoroughly performed to reduce the risk of recurrence. The incisal tooth region and the premolar regions are the most frequently affected regions (4) but the molar region involvement, which we present in our case, is rare (5-7).

Peripheral giant cell granuloma may cause nonspecific signs and symptoms depending on the level of involvement, such as bleeding, nose-

bleed, pain, tooth loss, and swelling (6-8). Our patient complained of bleeding during tooth brushing. The lesion may grow during pregnancy like other hyperplastic lesions of the oral cavity (9).

The pathological distinguishing feature of PGCG is the large number of giant cells localized in the oral mucosal stroma. The cause of this reactive response and cell source is still unclear, but osteoblasts, phagocytes, fusiform cells and endothelial cells are thought to be the source (10, 11). We need to examine microscopic features to be able to identify PGCG. A characteristic lesion includes a great number of giant cell foci with nuclei and hemosiderin fragments in the connective tissue stroma. Additionally, the surface epithelium of the mass is hyperplastic, no matter whether or not ulceration occurs at the base line. The treatment of PGCG is surgical excision with the accompanying bone tissue (1).

Although its relationship with real cause and local irritant factors are still unclear, local irritant factors, such as cigarette smoking, infection, and foreign body reaction should be avoided. Surgical excision should be performed after the irritant factors are controlled.

To reduce the risk of recurrence, surgical excision should remove the entire lesion. The recurrence rate is seen to vary in the studies, but the risk is around 10% in general (3). The importance of total surgical excision was also emphasized in previous reports (4, 5). If the lesion is superficially excised, the possibility of recurrence is very high. The tumor must be completely excised with the accompanying tooth and bone tissue to prevent recurrence of the lesion. We would like to emphasize the importance of the total excision of PGCG to reduce the risk of recurrence.

CONCLUSION

Peripheral giant cell granuloma is one of the common hyperplastic lesions of the oral cavity. When we detect a mass in the oral mucosa and gingiva, we need to consider this diagnosis. The main treatment for this pathology is total surgical excision.

Informed Consent: Written informed consent was obtained from patient who participated in this case.

Peer-review: Externally peer-reviewed.

Author Contributions: Concept – S.A., M.G.D., B.D., N.Y.Ü., S.K.; Design – S.A., M.G.D., B.D., N.Y.Ü., S.K.; Supervision – S.A., M.G.D., B.D., N.Y.Ü., S.K.; Resources – S.A., M.G.D., B.D., N.Y.Ü., S.K.; Materials – S.A., M.G.D., B.D., N.Y.Ü., S.K.; Data Collection and/or Processing – S.A., M.G.D., B.D., N.Y.Ü., S.K.; Analysis and/or Interpretation – S.A., M.G.D., B.D., N.Y.Ü., S.K.; Literature Search – S.A., M.G.D., S.K.; Writing Manuscript – S.A., M.G.D., N.Y.Ü., S.K.; Critical Review – S.A., M.G.D., S.K.

Conflict of Interest: No conflict of interest was declared by the authors.

Financial Disclosure: The authors declared that this study has received no financial support.

REFERENCES

1. Neville BW, Damm DD, Allen CM, Bouquot JE. Soft tissue tumors. In: Neville BW, Damm DD, Allen CM, Bouquot JE, editors. *Oral and Maxillofacial Pathology*. 3rd ed. Louis: Saunders Publishers; 2009.pp.507-63.
2. Kfir Y, Buchner A, Hansen LS. Reactive lesions of the gingiva: a clinicopathological study of 741 cases. *J Periodontol* 1980; 51: 655-61. [\[CrossRef\]](#)
3. Katsikeris N, Kakarantza-Angelopoulou E, Angelopoulos AP. Peripheral giant cell granuloma. Clinicopathologic study of 224 new cases and review of 956 reported cases. *Int J Oral Maxillofac Surg* 1988; 17: 94. [\[CrossRef\]](#)
4. Karlı F, Ugur ME, Bahadır B, Gul A, Uzun L. Giant cell peripheral granuloma: case report. *KBB-Forum* 2009; 8: 39-43.
5. Erdur O, Kayhan FT, Toprak MS, Aktas O. Peripheral giant cell granuloma: case report. *Bakirkoy Tip Dergisi* 2008; 4: 122-5.
6. Garg P, Jain J, De N, Chatterjee K. A central giant cell granuloma in posterior part of maxilla-A case report. *Int J Surg Case Rep* 2017; 30: 222-5. [\[CrossRef\]](#)
7. Faverani LP, Ferreira S, Ferreira GR, Colete JZ, Aranega AM, Garcia Junior IR. Central giant cell granuloma in pediatric maxilla: surgical management. *J Craniofac Surg* 2014; 25: e344-6.
8. Ciorba A, Altissimi G, Giansanti M. Giant cell granuloma of the maxilla: case report. *Acta Otorhinolaryngol Ital* 2004; 24: 26-9.
9. Oregan EM, Gibb DH, Odel EW. Rapid growth of giant cell granuloma in pregnancy treated with colchicine. *Oral Surg Oral Med Oral Pathol Oral Radiol Endod* 2001; 92: 532-8. [\[CrossRef\]](#)
10. Rajendran R. Benign and malignant tumors of the oral cavity. In: Rajendran R, Sivapathasundharam B, editors. *Shafer's Textbook of Oral Pathology*. 5th ed. New Delhi: Elsevier Publishers; 2006.pp.113-308.
11. Mannem S, Chava VK. Management of an unusual peripheral giant cell granuloma: A diagnostic dilemma. *Contemp Clin Dent* 2012; 3: 93-6. [\[CrossRef\]](#)